

Bronchoscopic Management of Bronchopleural Fistula

P. Gogia, S. Gupta and R. Goyal

Centre for Respiratory Diseases and Critical Care, Jaipur Golden Hospital, Rohini, New Delhi, India

ABSTRACT

In recent years successful bronchoscopic management of bronchopleural fistulas (BPFs) by locating its site and then blocking the leaking segment with any of the several agents available has gained recognition. It is now considered as an alternate mode of management of BPF. Here we present a case of non-resolving pneumothorax that was managed successfully using bronchoscopic glue (cyanoacrylate glue) instillation. [Indian J Chest Dis Allied Sci 2010;52:161-163]

Key words: Bronchopleural fistula, Cyanoacrylate glue, Bronchoscopic management.

INTRODUCTION

A bronchopleural fistula (BPF) is a communication between the pleural space and the bronchial tree. Persistent bronchopleural fistulas (BPFs) represent a challenging problem to manage and are associated with prolonged morbidity and mortality. The BPF may occur due to rupture of a lung abscess, bulla or cyst, due to barotrauma, erosion by an inflammatory process and malignancy, breakdown of a suture line after pulmonary resection and physical trauma — accidental or iatrogenic (lung biopsy or chest tube insertion) or spontaneous. The initial approach is tube thoracostomy and suction but BPFs that do not heal by this treatment are subjected to surgery. However, surgery may not be feasible due to extensive underlying lung disease, comorbidity, poor general condition or advanced age. Various non-surgical bronchoscopic methods using an array of materials, such as gel foam, cyanoacryl glue, ethanol have been reported in the literature. Here we describe a case of BPF with non-resolving pneumothorax that was successfully managed by bronchoscopic cyanoacrylate glue instillation at the site of the BPF. Complete expansion of the lung and closure of BPF were achieved.

CASE REPORT

A 50-year-old female, housewife, and a previously diagnosed case of chronic obstructive airway disease with a history of old treated pulmonary tuberculosis presented with an acute onset of breathlessness of a few hours. She had developed fever with cough and mucoid expectoration for two days prior to the onset

of breathlessness. On examination, the percussion note was hyperresonant and auscultation revealed absence of breath sounds on the right side. A chest radiograph (postero-anterior view) revealed a right-sided pneumothorax. Intercostal drainage (ICD) tube was inserted immediately and the patient felt better. Intravenous antibiotics and bronchodilators were administered. Sputum was sent for pyogenic culture, acid-fast bacilli (AFB) smear and rapid culture for AFB. The pyogenic culture was sterile and two sputum samples for AFB were negative. In the days to follow, the ICD continued to show an air leak with no significant expansion on the right side (Figure 1).

After waiting for four days for spontaneous closure of BPF, a bronchoscopy was performed to rule out

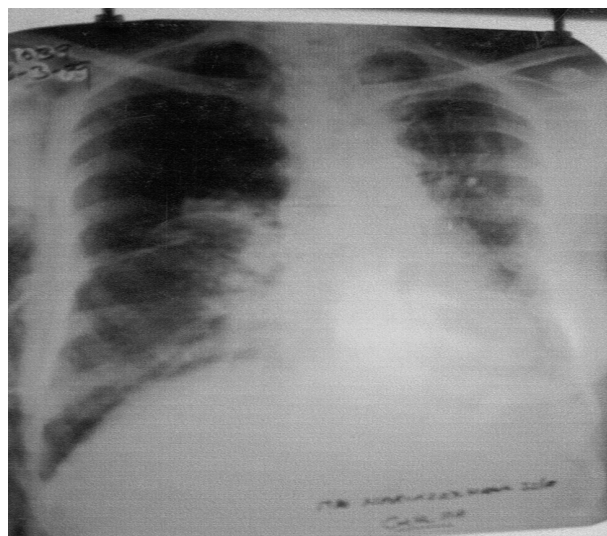


Figure 1. Chest radiograph showing ICD tube with the collapsed lung.

[Received: June 24, 2009; accepted after revision: March 12, 2010]

Correspondence and reprint requests: Dr Pratibha Gogia, Consultant, Centre for Respiratory Diseases and Critical Care, Jaipur Golden Hospital, Sector 3, Rohini, New Delhi - 110 085, India; Phone: 9891170363; E-mail: Pratibha_gupta3@yahoo.com

any intrabronchial obstruction. No intrabronchial lesion was seen. In the same sitting, an attempt was made to localise the site of the BPF by serially blocking various lung segments, through wedging the bronchoscope in each segment. The air leak significantly decreased on wedging the tip of the bronchoscope in the right upper lobe apical segment. To inject this glue, a 100cm long 21 G catheter with a diameter of 1.8mm was used. The tip of this catheter was placed in the segment that was earlier localised. Cyanoacrylate glue (0.5–1mL) was injected through this catheter after loading it in a 5 mL syringe along with 4mL of air and connecting it with the proximal end of the catheter. Cyanoacrylate glue was then instilled in the right upper lobe apical segment using a 20 fr needle. The air leak stopped immediately and the patient's ICD tube was connected to a low pressure suction device. Chest radiograph done next day showed partial expansion of the lung with surgical emphysema. The ICD was left *in situ* and negative pressure suction continued. A chest radiograph done subsequently showed complete expansion of the lung after two days (Figure 2).

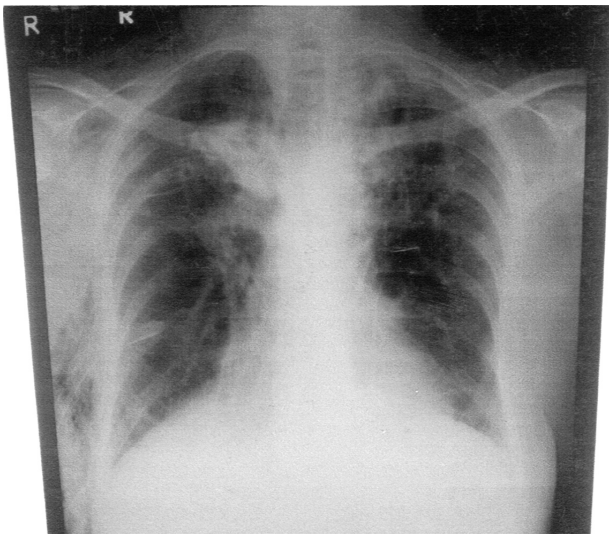


Figure 2. Chest radiograph showing ICD tube with the expanded lung.

A plain CT thorax was done to confirm complete expansion of the lung (Figure 3). Pleurodesis was then carried out using povidone iodine as it was a case of secondary spontaneous pneumothorax and the ICD was removed. On follow-up, she continued to be asymptomatic.

DISCUSSION

Managing BPF is often a challenge. A tube thoracostomy is often successful as the BPF heals spontaneously. However, if it fails, the patient may

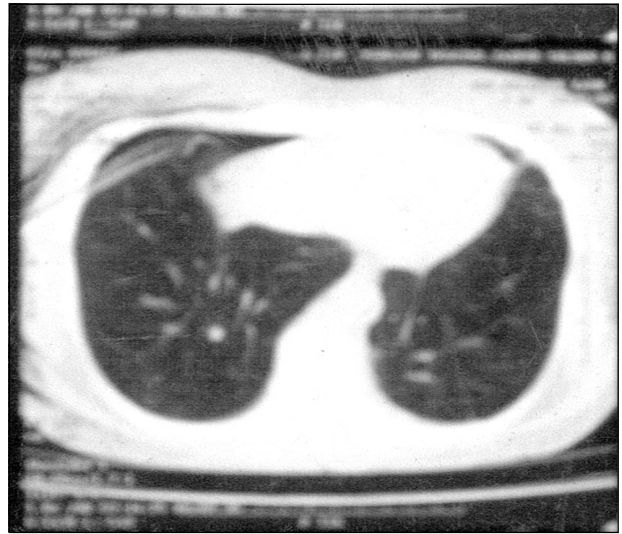


Figure 3. CT thorax showing the ICD tube with the fully expanded lung.

require one of the various surgical forms of treatment, including direct repair of the fistula, thoracoplasty, myoplasty, omental transposition and lung resection, that is lobectomy or pneumonectomy.¹

A new approach of treating BPFs bronchoscopically is being increasingly used. The bronchoscopist tries to establish the site of the BPF either by wedging the bronchoscope in each segment and simultaneously observing whether the air bubbles cease or decrease. The other way of establishing the site of the BPF is to use a Fogarty's balloon, passing it through the bronchoscope and "inflating" it in each segment and then observing the decrease in the air leak. Once the site of the BPF is established, a thin catheter is passed through the bronchoscope and the tip of catheter is placed in the identified segment as distally as possible. There are various embolic agents that can be injected through the catheter to seal the BPF. The commonly used agents are blood clots, gelatin, and gelatin capsule shaped silicon rubber plugs, machine brass screws, gel foams, ethyl alcohol, tetracycline, fibrin glue, cyanoacrylate glue and metallic coils.² We selected cyanoacrylate glue, as it is inexpensive, easily available and simple to use. If incomplete closure of the fistula occurs then the procedure can be repeated in the same setting with another shot of the glue. The only technical consideration with this agent is that, it has to be injected through a catheter to prevent damage to bronchoscope channel. The tip of the catheter is kept well away from the tip of the bronchoscope to prevent accidental spill of the glue in the bronchoscope. This glue mechanically occludes the fistula and induces a local reaction causing proliferation of the bronchial mucosa. This proliferation process is responsible for long-term closure of the fistula.³

In 1977, Rattiff and Colleagues,⁴ reported for the first time successful closure of a BPF by endobronchial occlusion with a lead shot. That same year Hartmann and Rausch⁵ described a new therapeutic application of fiberoptic bronchoscope, that is, closure of a BPF by endoscopic application of tissue glue. Since then numerous case reports and small case series have documented successful endobronchial control of BPF with fiberoptic bronchoscope. However, in India only one such case report has been published where the author instilled gel foam using the fiberoptic bronchoscope.⁶ *To be best of our knowledge, this is first case report from India where cyanoacrylate glue was used to heal the BPF.*

The advent of flexible bronchoscopy has improved localisation of small peripheral fistulas. If successful, this technique eliminates the risk of general anaesthesia and major surgery. Clearly, the role of the interventional bronchoscopist is expanding and as a result the contemporary clinical practice employs a comprehensive and individualised therapeutic plan

that is created for the unique needs of the patient and is least invasive.

REFERENCES

1. Jain R, Baijal SS, Phadke RV, Pandey CK, Saraswati VA. Endobronchial closure of a bronchopleural cutaneous fistula using angiography catheters. *AJR Am J Roentgenol* 2000;175:1648-9.
2. McManigle JE, Fletcher GL, Tenholder MF. Bronchoscopy in the management of bronchopleural fistula. *Chest* 1990;97:1235-8.
3. Menard JW, Prejean CA, Tucker WY. Endoscopic closure of bronchopleural fistula using a tissue adhesive. *Am J Surg* 1988;155:415-6.
4. Rattiff JL, Hill J, Tuchu H, Fallat R. Endobronchial control of bronchopleural fistula. *Chest* 1977;71:98-9.
5. Hartman W, Rausch V. A new therapeutic application of fiberoptic bronchoscope. *Chest* 1977;71:237.
6. Shah AM, Singhal P, Chhajed PN, Athavale A, Krishnan R, Shah AC. Bronchoscopic closure of bronchopleural fistula using gelfoam. *J Assoc Physicians India* 2004;52: 508-9.